



Free Questions for MBLEx

Shared by Bradshaw on 16-04-2026

For More Free Questions and Preparation Resources

[Check the Links on Last Page](#)



Question 1

Question Type: MultipleChoice

What are the ideal times to perform an assessment of the client to understand problem areas and the effectiveness of treatment?

Options:

- A- After the treatment
- B- During the treatment
- C- A massage therapist who is extra friendly with a client who shares the same hobbies
- D- A and b only

Answer:

A

Explanation:

Before starting treatment with a client, a massage therapist must first understand what the nature of the client's complaint is, whether the condition is indicated or contraindicated or if a referral is necessary. Once the therapy session is complete, an assessment is necessary to determine the benefit of the treatment to the client.

Question 2

Question Type: MultipleChoice

Which option best is not part of the small intestine?

Options:

- A- Duodenum
- B- Jejunum
- C- Sigmoid
- D- Ilium

Answer:

C

Explanation:

The sigmoid colon is part of the large intestine that is closest to the anus.

Question 3

Question Type: MultipleChoice

The radial nerve divides into a deep branch called the _____ nerve?

Options:

- A- musculocutaneous
- B- anterior interosseous
- C- palmar digital
- D- posterior interosseous

Answer:

D

Explanation:

The radial nerve divides into the superficial dorsal digital nerves and the deeper posterior interosseous nerve, located at the posterior aspect of the forearm.

Question 4

Question Type: MultipleChoice

A crackling, grating or popping sound from joints is referred to as _____.

Options:

- A- air bubbles
- B- a soft tissue barrier
- C- crepitus
- D- a degenerative disease

Answer:

C

Explanation:

Crepitus is a crackling, grating or popping sound from joints or other subcutaneous tissue.

Question 5

Question Type: MultipleChoice

A client with a valgus deformity is also described as being _____.

Options:

- A- knock kneed
- B- pigeon toed
- C- hump backed
- D- double jointed

Answer:

A

Explanation:

A valgum deformity is an outward angulation of the distal segment of a joint or bone. In other words, the knees will be angled medially and the feet will be angled laterally. Reverse this scenario to laterally angled knees and medially angled feet and you will see a varum deformity also known as bow legged.

Question 6

Question Type: MultipleChoice

Choose the correct definition of the anatomical term "linea".

Options:

- A- A passage or canal
- B- A line or long ridge
- C- A hole or opening
- D- A meeting point of two or more bones



Answer:

B

Explanation:

The anatomical term "linea" refers to a line or long ridge, such as the attachment site of the hamstrings along the linea aspera on the posterior aspect of the femur.

Question 7

Question Type: MultipleChoice

Where would you locate the annular ligament?



Options:

- A- Knee
- B- Ankle
- C- Wrist
- D- Elbow

Answer:

D

Explanation:

The annular ligament stabilizes the proximal radius against the ulna during pronation and supination of the wrist. The ligament is located deep to the supinator and origin of the extensor muscles of the forearm near the head and proximal shaft of the radius at the elbow.

Question 8

Question Type: MultipleChoice

What condition is Phalen's test used to assess?



Options:

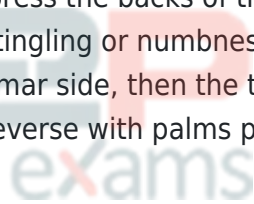
- A- Thoracic outlet syndrome
- B- Piriformis syndrome
- C- Radial tunnel syndrome
- D- Carpal tunnel syndrome

Answer:

D

Explanation:

The Phalen's test requires the client to firmly press the backs of the hands together for a duration up to a minute. If the client experiences pain, tingling or numbness in the thumb, index, middle and lateral half of the ring finger along the palmar side, then the test is positive for a carpal tunnel compression. The test can be done in reverse with palms pressed firmly together.



To Get Premium Files for MBLEx Visit

<https://www.p2pexams.com/products/mblex>

For More Free Questions Visit

<https://www.p2pexams.com/fsmtb/pdf/mblex>

20%
DISCOUNT

P2P
exams